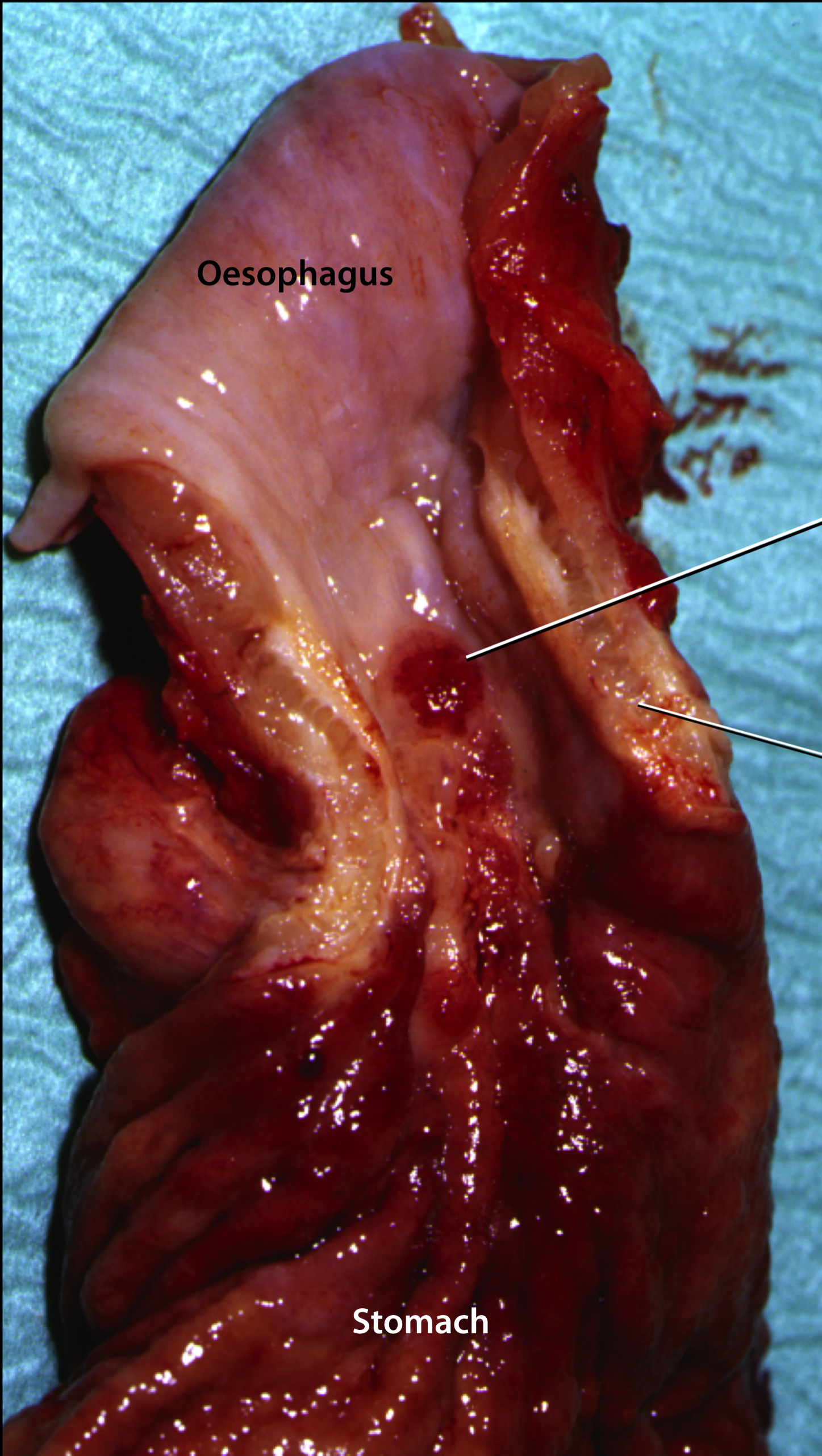


Surgical specimen showing an adenocarcinoma of the lower oesophagus



Oesophagus

Ulcerating carcinoma

Submucous infiltration

Stomach